

Evidence 7

Dr Shaw's Expert Independent Radiology Report on Mr Dutt's HSG of 1986

AMI Portland Hospital for Women and Children



100, Portland Street
WIMBORNE
DORSET DT9 4JQ
Tel: 01305 31110

SW

Date: 15th November 1991

GP Not Known
c/o Ami Portland Hospital

Phillipa Langton
Mr. J. Glatt MRCP MRCOG
Infertility Advisory, 3 Spanis

Manchester Square,

DoB. 00.00.0000

Hospital No. 4004204

Radiology Report:

REPORTING ON FOREIGN FILM (11.10.91)

HYSTEOSALPINGOGRAM Taken at the Royal Northern Hospital 3.12.86

I did not have the benefit of the fluoroscopic findings, but the right fallopian tube appears well outlined and there is peritoneal spill. The appearance of the left tube is unusual. The proximal part is reasonably seen and part of what I take to be the distal part running more medially is also seen but details of the fimbriae are not visible on this radiograph. Close to the interruption of the column there are two small short parallel opacities. Has there been any operative intervention in relation to the left tube or is there any history of application of clips etc, in this region. Is there any relevant history. I would be pleased to discuss this further if you wish over the telephone.

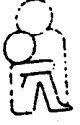Dictated NOT SIGNED: 11.10.91

ADDITIONAL REPORT: 18.11.91

1754

112


AMI Portland Hospital for Women and Children



3000 N. Portland Street,
Portland, OREGON
Telephone: 4400
1970

The body of the uterus looked basically normal.

Dictated but not signed:


Dr D Shaw

1755

113